

## The Relationship between the Flexible Flatfoot and Plantar Fasciitis: Ultrasonographic Evaluation

Yu-Chi Huang, MD; Lin-Yi Wang, MD; Her-Cherng Wang, MD; Kai-Lan Chang, MD;  
Chau-Peng Leong, MD

**Background:** The purpose of this study was to investigate the relationship between flexible flatfoot and plantar fasciitis.

**Methods:** Twenty-three subjects with flexible flatfoot and 23 subjects with normal arched feet were enrolled. Footprint analysis was used to evaluate the foot conditions in both groups to calculate the individual arch index. We compared the sonographic images of plantar fascia in the flexible flatfoot group with the normal arch group using high-frequency ultrasound.

**Results:** The analysis results indicated that the thickening of the plantar fascia in the flexible flatfoot group was significantly different from the normal arch group. In the flexible flatfoot group, 10 of 23 patients (43.4%) had plantar fasciitis, but only two subjects (8.7%) in the normal arch group had plantar fasciitis.

**Conclusions:** There was a higher incidence of plantar fasciitis in the flexible flatfoot group than the normal arch control group in this study.

(*Chang Gung Med J* 2004;27:443-8)

**Key words:** flatfoot, plantar fascia, ultrasonography.

Flexible flatfoot is defined as the postural appearance of the foot, with depressed medial longitudinal arch and pronated subtalar joint and the calcaneus assuming a valgus position under weight bearing conditions.<sup>(1)</sup> About 10% to 25% population exhibits a flatfoot to varying degrees.<sup>(2)</sup> In clinical practice, some subjects become symptomatic with foot pain or lower extremity soreness and limitation in their functional activities such as limitation of long distance walking or running and high-impact sports.

Anatomically, the major medial longitudinal arch is formed by the calcaneus, talus, and navicular; the medial, middle, and lateral cuneiforms in addition to the 1st, 2nd, 3rd metatarsals. In dynamic

structures, the plantar fascia is essential to the maintenance of the medial longitudinal arch.<sup>(3,4)</sup> Kitaoka and associates demonstrated that the posterior tibial tendon owns significant influence as an arch stabilizer during in vitro studies.<sup>(5,6)</sup> The intrinsic musculature of the foot was also proven to have a significant role in dynamic arch maintenance.<sup>(2,7)</sup>

Plantar fasciitis is the most common cause of the inferior heel pain and may affect up to 10% of running athletes.<sup>(8-11)</sup> It is associated with biomechanical factors such as pes cavus, foot pronation, heel valgus, sudden gain in body weight or obesity, increased running distance or intensity, shoes with poor cushioning, change in the walking or running surface, and tightness of the Achilles tendon.<sup>(10,12-15)</sup>

---

From the Department of Rehabilitation Medicine, Chang Gung Memorial Hospital, Kaohsiung.

Received: Dec. 16, 2003; Accepted: Feb. 20, 2004

Address for reprints: Dr. Chau-Peng Leong, Department of Physical Medicine and Rehabilitation, Chang Gung Memorial Hospital, 123, Dabi Road, Niasung Shiang, Kaohsiung, Taiwan 833, R.O.C. Tel.: 886-7-7317123 ext. 8373; Fax: 886-7-5576324; E-mail: cpleong@cgmh.org.tw

Very few studies have been performed to evaluate the flat foot condition using ultrasonography. The aims of this study were to explore the plantar fascia and posterior tibial tendon of the flexible flat foot and to assess the relationship between arch index and plantar fasciitis.

## METHODS

Each footprint was taken by chalking the sole of the foot and making an impression of it on paper (APEX, total contact foot imprinter system). Based on the methods used in the study by Staheli et al.,<sup>(16)</sup> we measured the width of the foot in the area of the arch and the width of the heel, and the former number was divided by the latter one to calculate the arch index for each foot (Fig. 1). After the middle stages of childhood, the arch index has a board normal range from about 0.3 to 1.0 through adulthood.<sup>(16)</sup> The 46 subjects in this study were then grouped by the arch index criteria (the flexible flatfoot group had arch indexes of more than 1.0).

Forty-six volunteer hospital personnel and outpatients were randomly selected for the analysis, of which 23 subjects with normal arches (46 feet; 14 men, 9 women; aged 13-61 years old; mean,  $31.0 \pm$

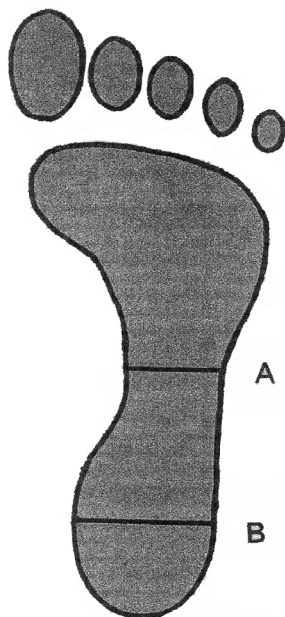
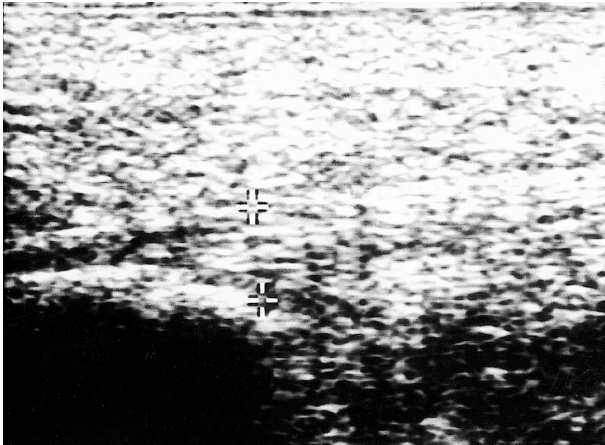


Fig. 1 Arch index: A/B

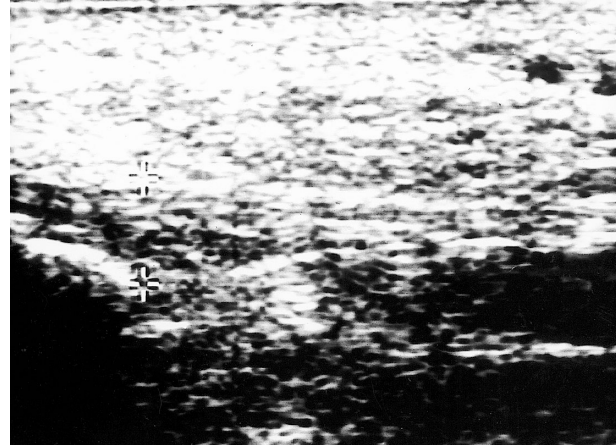
12.3 years old) and 23 subjects with flexible flatfoot (46 feet; 15 men, 8 women; aged 11-60 years old; mean,  $30.3 \pm 15.1$  years old) were enrolled in this study. All subjects underwent footprint and medical history screening. The exclusion criteria were foot injury including any bony pathology or ligament injury, degenerative or rheumatoid arthritis and other musculoskeletal abnormalities that were previously evaluated during physical examination or plain X-ray.

The 46 subjects were evaluated in terms of high-frequency sonography with linear 10-5 MHz transducer (Acuson, Aspen model). All subjects underwent examinations of both heels as they were lying in a prone position with their feet hanging over the edge of examination table.<sup>(16)</sup> The sagittal sonographic images were obtained over the plantar area of the foot, and the thickness of the plantar fascia was measured at its proximal end over its insertion to the calcaneus (Figs. 2 and 3). The ultrasonography protocol of posterior tibial tendon included longitudinal and transverse scans at the level of the medial malleolus. The high-frequency ultrasonography examinations were all done by the same physiatrist who is familiar with the techniques of evaluating feet. The ultrasound results were recorded for thickness, echogenicity, and fiber discontinuity of both the plantar fascia and posterior tibial tendon, the fluid accumulation and anechoic or hypoechoic tissue in peritendinous area, and any flow within the tendons and peritendinous area using color and power Doppler. Plantar fascia thickening by ultrasound was defined as greater than 4 mm in this fascia. Posterior tibial tendonitis by ultrasound was defined as increased flow or hypoechoic change in that tendon. Tenosynovitis was defined as the increase in flow or increased fluid ( $> 4$  mm) surrounding that tendon. Plantar fasciitis was diagnosed by the presence of heel pain with local tenderness and correlated with plantar fascia thickening.

All footprint and sonographic data are shown as the mean  $\pm$  standard deviation. Differences were analyzed using t-test analysis for arch index, sonographic data, and their clinical parameters. Chi-square test was used for gender. Fisher's exact test was used for the relationship between the plantar fasciitis and plantar fascia thickening. Results with a *p* value  $< 0.05$  were considered statistically significant.



**Fig. 2** Plantar fascia: longitudinal ultrasound. The plantar fascia appears normal echogenicity and thickened and measures 4.8 mm.



**Fig. 3** Plantar fasciitis: longitudinal ultrasound. The plantar fascia appears hypoechoic and thickened and measures 5.4 mm.

## RESULTS

The demography in these two groups are listed in Table 1. There were no significant differences in age, gender ratio, height, body weight, and body mass index (BMI) between these two groups. Tracing their clinical history, 12 subjects in the flexible flatfoot group had heel pain and only two subjects with normal arches had heel pain.

The mean arch indices of the right foot of the normal arch group and flexible flatfoot group respectively were  $0.66 \pm 0.11$  and  $1.29 \pm 0.21$ . The mean arch indices of the left foot of the normal arch group and flexible flatfoot group respectively were  $0.65 \pm 0.12$  and  $1.36 \pm 0.17$ . Sonography of the bilateral plantar fascia revealed the mean plantar fascia thickness of the right foot of the normal arch group and flexible flatfoot group respectively were  $0.33 \pm 0.04$  cm and  $0.39 \pm 0.10$  cm. The mean plantar fascia thickness of the left foot of the normal arch group and flexible flatfoot group respectively were  $0.33 \pm 0.05$  cm and  $0.39 \pm 0.06$  cm. All variables measured were significantly different between these two groups (Table 2). Additionally, there were nine subjects with hypoechoic in the flexible flatfoot group, but no hypoechoic changes of the plantar fascia were found in the normal control group. No calcifications or tears in the plantar fascia were found in these two groups. The posterior tibial tendons were all intact without any echogenicity changes or

**Table 1.** Clinical Parameters: the Flatfoot Group vs. the Control Group

	Flatfoot group (N = 23)	Control group (N = 23)	<i>p</i>
Age (years)	30.3 ± 15.1	31.0 ± 12.3	0.87
Sex (men/women)	15/8	14/9	0.76
Height (cm)	165.5 ± 8.1	167.2 ± 6.7	0.43
Body weight (kg)	65.1 ± 13.1	61.5 ± 10.1	0.30
BMI	23.7 ± 3.7	22.8 ± 5.7	0.54

**Table 2.** Ultrasonographic Findings and Clinical Symptoms of the Flatfoot Group vs. the Control Group

	Flatfoot group (N = 23)	Control group (N = 23)	<i>p</i>
The thickness of the plantar fascia; right (cm)	0.39 ± 0.10	0.33 ± 0.04	0.004*
The thickness of the plantar fascia; left (cm)	0.39 ± 0.06	0.33 ± 0.05	0.002*
Plantar fascia thickening without heel pain	15 (65.2%)	2 (8.7%)	<0.001*
Plantar fascia thickening with heel pain	10 (43.4%)	2 (8.7%)	0.008*

**Table 3.** The Relationship between Plantar Fasciitis and Plantar Fascia Thickening in the Flatfoot Group (N = 23)

	With plantar fascia thickening	Without plantar fascia thickening	<i>p</i>
With plantar fasciitis	10	0	0.003*
Without plantar fasciitis	5	8	

tenosynovitis in these 46 cases. In the normal control group, only two subjects had unilateral plantar fascia thickening without any hypoechoic changes (2/23; 8.7%) and they both suffered from heel pain. In the flatfoot group, 10 of 15 subjects with plantar fascia thickening had heel pain (7/10: unilateral plantar fasciitis; 3/10: bilateral plantar fasciitis). Five of 15 subjects with plantar fascia thickening had no clinical symptoms (4/5: unilateral plantar fascia thickening; 1/5: bilateral plantar fascia thickening) (Table 2). The relationship between the plantar fasciitis and plantar fascia thickening was statistically significant (Table 3).

## DISCUSSION

In the case of flexible flatfoot, the subtalar joint remains pronated after foot is flat and midtarsal joint is not locked.<sup>(1)</sup> When abnormal weight-bearing condition persists and the talocalcaneus joint gets chronically subluxed, the foot cannot support the rigid propulsion for the normal gait cycle. After heel strike during the first half of the stance phase of the gait cycle, the tibia turns inward and the foot excess pronates to allow flattening of the foot. This mechanism stretches the plantar fascia.<sup>(15)</sup> As the foot progresses from foot-flat to push-off, the toes dorsiflex and the plantar fascia tightens. As the plantar fascia extends distal to the metatarsal head, tension causes the head to depress and the arch to rise. The plantar fascia pulls on its medial tubercle origin with more effort to create calcaneus inversion in a flatfoot subject with heel valgus.<sup>(3,17)</sup> Therefore, the repetitive traction placed on the plantar fascia during walking or running may lead to microtears and inflammatory response.<sup>(18)</sup> The plantar fascia which arises predominantly from the medial calcaneal tuberosity and its main structure that fans out to be inserted into the plantar surface of the metatarsophalangeal joints has an important function in maintaining the medial longitudinal arch.<sup>(15)</sup>

Plantar fasciitis that was diagnosed by the presence of heel pain with local tenderness and correlated with plantar fascia thickness is a common clinical morbidity. Hypoechoic thickening of the plantar fascia greater than 4 mm in the symptomatic patient is consistent with the diagnosis of plantar fasciitis.<sup>(19-21)</sup> The pain is usually localized to the area medial to calcaneal tuberosity and is the worst on the first

weight bearing action in the morning.<sup>(15)</sup> After a few steps, heel pain decreases throughout the day but worsens with increased activity. Plantar fasciitis is the most common condition in middle-aged women and younger runners, with a male predominance.<sup>(8-11)</sup>

Many authors have described the tenosynovitis, rupture of the posterior tibial tendon was co-related with acquired flatfoot,<sup>(22-24)</sup> and echogenic changes or subluxation in the tendons was also found in previous studies.<sup>(22-24)</sup> In our 23 subjects of the congenital flexible flatfoot group, no abnormal findings were noted during the ultrasonography examinations.

Most of the previous studies about flat feet have focused on biomechanical deficit, methods for evaluation and treatment. In this study, sonography was used to evaluate the changes of the plantar fascia in the flatfoot subjects. In the flexible flatfoot group, the results indicated that the plantar fascia was thickened (> 4 mm) in 15 subjects (15/23; 65.2%) and correlated to the hypoechoic changes in nine subjects. In the flatfoot group, 10 of 23 subjects with plantar fascia thickening had heel pain.

In conclusion, the above results show that 10 subjects (10/23; 43.4%) in the flatfoot group suffered from plantar fasciitis, thus there was a significantly higher incidence of plantar fasciitis in the flexible flatfoot subjects.

## REFERENCES

1. Leung AKL, Mak AFT, Evans JH. Biomechanical gait evaluation of the immediate effect of orthotic treatment for flexible flatfoot. *Prosthet Orthot Int* 1998;22:35-44.
2. Anderson RB, Davis WH. Management of the adult flatfoot deformity. In: Myerson MS. *Foot and Ankle Disorders*. 1st ed. Philadelphia: WB Saunders, 2000: 1017-25.
3. Sellman JR. Plantar fascia rupture associated with corticosteroid injection. *Foot Ankle Int* 1994;15:376-81.
4. Daly PJ, Kitaoka HB, Chao EYS. Plantar fasciotomy for intractable plantar fasciitis: clinical results and biomechanical evaluation. *Foot Ankle* 1992;13:188-95.
5. Kitaoka HB, Ahn TK, Luo ZP, An KN. Stability of the arch of the foot. *Foot Ankle Int* 1997;18:644-8.
6. Kitaoka HB, Luo ZP, An KN. Effect of the posterior tibial tendon on the arch of the foot during simulated weight-bearing: biomechanical analysis. *Foot Ankle Int* 1997; 18:43-6.
7. Mann RA, Inman VT. Phasic activity of intrinsic muscles of the foot. *J Bone Joint Surg Am* 1964;46:469.
8. Baxter DE. The heel in sports. *Clin sports Med* 1994;13:

- 683-93.
9. DeMaio M, Paine R, Mangine RE, Drez D. Plantar fasciitis. *Orthopedics* 1993;16:1153-63.
  10. Schepsis AA, Leach RE, Gorzyca J. Plantar fasciitis: etiology, treatment, surgical results, and review of the literature. *Clin Orthop Rel Res* 1991;256:185-96.
  11. Campbell JW, Inman VT. Treatment of plantar fasciitis and calcaneal spurs with the UCBL shoe insert. *Clin Orthop* 1974;103:57-62.
  12. Amis J, Jennings L, Graham D, Graham CE. Painful heel syndrome: radiographic and treatment assessment. *Foot Ankle* 1988;9:91-5.
  13. Kibler WB, Goldberg C, Chandler TJ. Functional biomechanical deficits in running athletes with plantar fasciitis. *Am J Sports Med* 1991;19:66-71.
  14. Messier SP, Pittala KA. Etiologic factors associated with selected running injuries. *Med Sci Sports Exercise* 1988;20:501-5.
  15. Singh D, Angel J, Bentley G, Trevino SG. Fortnightly review: Plantar fasciitis. *BMJ* 1997;315:172-5.
  16. Staheli LT, Chew DE, Corbett M. The longitudinal arch. *J Bone Joint Surg Am* 1987;135:107-18.
  17. Kitaoka HB, Luo ZP, Growney ES, Berglund LJ, An KN. Material properties of the plantar aponeurosis. *Foot Ankle Int* 1994;15:557-60.
  18. Leach RE, Seavey MS, Salter DK. Results of surgery in athletes with plantar fasciitis. *Foot Ankle* 1986;7:156-61.
  19. Cardinal E, Chhem RK, Beauregard CG, Aubin B, Pelletier M. Plantar fasciitis: sonographic evaluation. *Radiology* 1996;201:257-9.
  20. Gibbon WW, Long G. Ultrasound of the plantar aponeurosis. *Skeletal Radiol* 1999;28:21-6.
  21. Fessell DP, van Holsbeeck MT. Sonography of the ankle and foot. In: Introcaso JH, van Holsbeeck MT eds. *Musculoskeletal ultrasound*. 2nd ed. St. Louis: CV Mosby, 2001:619-20.
  22. Cozen L. Posterior tibial tenosynovitis secondary to foot strain. *Clin Orthop* 1965;42:101-2.
  23. Downey DJ, Simpkin PA, Richardson ML, Kilcoyne RF, Hansen ST. Tibialis posterior tendon rupture: a case of rheumatoid flat foot. *Arthritis Rheum* 1988;31:441-6.
  24. Funk DA, Cass J R, Johnson KA. Acquired adult flat foot secondary to posterior tibial tendon pathology. *J Bone Joint Surg Am* 1986;68:95-102.



## 使用超音波來評估非固定性扁平足和足底筋膜炎之間的關聯性

黃郁琦 王琳毅 王和誠 張凱嵐 梁秋萍

**背景：** 這篇研究目的是在探討非固定性扁平足和足底筋膜炎之間的關聯性。

**方法：** 我們收集了23位非固定性扁平足和23位有正常足弓的個案。藉著踩足印的方式來分析這兩組的足底情形，算出個別的足弓比值。我們使用高解析的肌肉骨骼超音波來比較非固定性扁平足組和正常足弓組，其足底筋膜的超音波影像。

**結果：** 我們發現非固定性扁平足組的足底筋膜明顯比正常足弓組的增厚許多。兩者的足底筋膜的厚度在統計學上有意義的差距。在非固定性扁平足這一組中，有10個患者有足底筋膜炎的情形，發生率為43.4%。但是在正常足弓組，只有2個患者有足底筋膜炎的情形，發生率為8.7%。

**結論：** 比較非固定性扁平足組和正常足弓組，我們發現非固定性扁平足組發生足底筋膜炎的比例較正常足弓組為高。

(長庚醫誌 2004;27:443-8)

**關鍵字：** 扁平足，足底筋膜炎，超音波。

---

長庚紀念醫院 高雄院區 復健科

受文日期：民國92年12月16日；接受刊載：民國93年2月20日。

索取抽印本處：梁秋萍醫師，長庚紀念醫院 復健科。高雄縣833鳥松鄉大埤路123號。Tel.: (07)7317123轉8373; Fax: (07) 5576324; E-mail: cpleong@adm.cgmh.org.tw